

## Bitot Spot

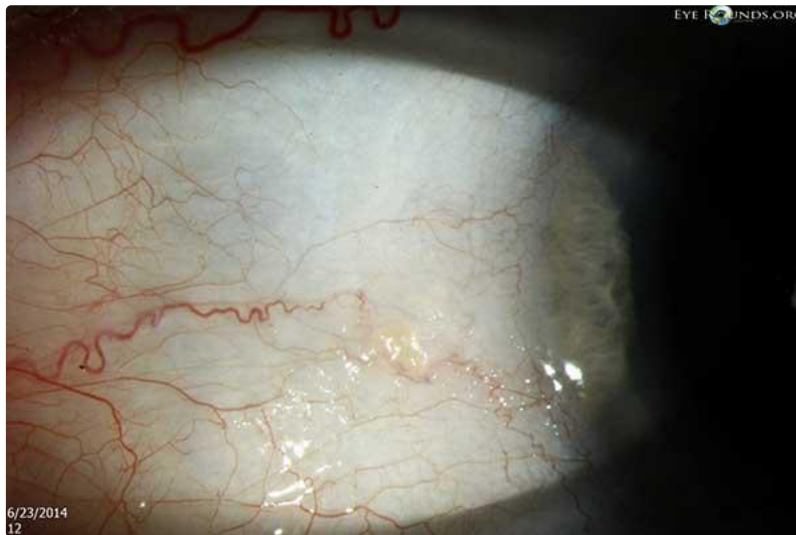
Category(ies): Cornea

Contributors: [Pavlina Kemp, MD](#) & [Mark Greiner, MD](#)

Photographer: Brice Critser, CRA

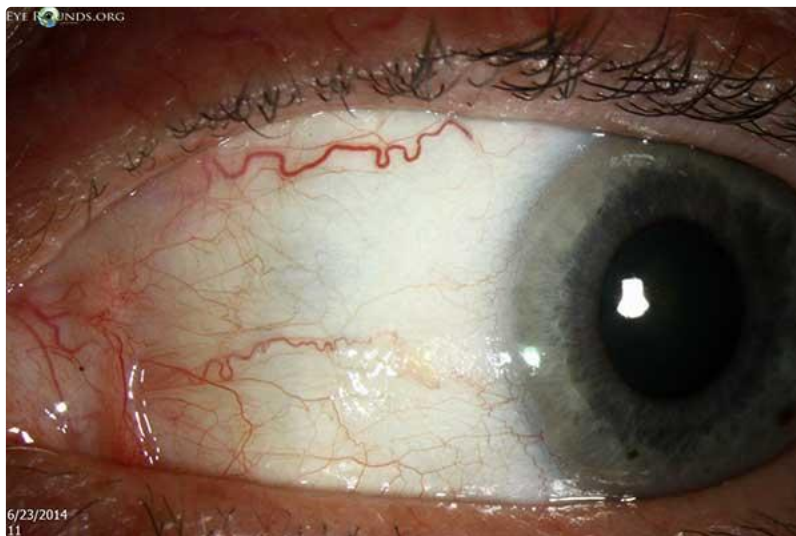


60-year-old woman with Bitot spot in the left eye with low serum levels of vitamin A, in the setting of chronic hepatitis C and near-daily alcohol use. Note the nasal white foamy patch about 3 x 3 mm on nasal bulbar interpalpebral conjunctiva.



[Enlarge](#)

[Download](#)



[Enlarge](#)

[Download](#)

---

## References:

1. Reddy PS. Bitot spots and vitamin A deficiencies. Trans Ophthalmol Soc N Z. 1965;17:90-3. PubMed PMID: 521723
- 

## Image Permissions:



Ophthalmic Atlas Images by [EyeRounds.org](http://EyeRounds.org), [The University of Iowa](http://The University of Iowa) are licensed under a [Creative Commons Attribution-NonCommercial-NoDerivs 3.0 Unported License](https://creativecommons.org/licenses/by-nc-nd/3.0/).

---

### Address

University of Iowa  
Roy J. and Lucille A. Carver College  
of Medicine  
Department of Ophthalmology and  
Visual Sciences  
200 Hawkins Drive  
Iowa City, IA 52242

[Support Us](#)

### Legal

Copyright © 2019 The University of  
Iowa. All Rights Reserved  
[Report an issue with this page](#)  
[Web Privacy Policy](#) |  
[Nondiscrimination Statement](#)

### Related Links

[Cataract Surgery for Greenhorns](#)  
[EyeTransillumination](#)  
[Gonioscopy.org](#)  
[Iowa Glaucoma Curriculum](#)  
[Iowa Wet Lab](#)  
[Patient Information](#)  
[Stone Rounds](#)  
[The Best Hits Bookshelf](#)

### EyeRounds Social Media

Follow



Receive notification of new cases,  
[sign up here](#)  
[Contact Us](#)  
[Submit a Suggestion](#)